

Restoring tibiofemoral alignment during ACL reconstruction results in better knee biomechanics

Frantzeska Zampeli^{1,2} · Ioannis Terzidis³ · João Espregueira-Mendes^{4,5} · Jim-Dimitris Georgoulis² · Manfred Bernard⁶ · Evangelos Pappas^{2,7} · Anastasios D. Georgoulis²

Received: 13 March 2017 / Accepted: 2 October 2017

© European Society of Sports Traumatology, Knee Surgery, Arthroscopy (ESSKA) 2017

Abstract

Purpose Anterior cruciate ligament (ACL) reconstruction (ACLR) aims to restore normal knee joint function, stability and biomechanics and in the long term avoid joint degeneration. The purpose of this study is to present the anatomic single bundle (SB) ACLR that emphasizes intraoperative correction of tibiofemoral subluxation that occurs after ACL injury. It was hypothesized that this technique leads to optimal outcomes and better restoration of pathological tibiofemoral joint movement that results from ACL deficiency (ACLD).

Methods Thirteen men with unilateral ACLD were prospectively evaluated before and at a mean follow-up of 14.9 (SD = 1.8) months after anatomic SB ACLR with bone patellar tendon bone autograft. The anatomic ACLR replicated the native ACL attachment site anatomy and graft

orientation. Emphasis was placed on intraoperative correction of tibiofemoral subluxation by reducing anterior tibial translation (ATT) and internal tibial rotation. Function was measured with IKDC, Lysholm and the Tegner activity scale, ATT was measured with the KT-1000 arthrometer and tibial rotation (TR) kinematics were measured with 3D motion analysis during a high-demand pivoting task.

Results The results showed significantly higher TR of the ACL-deficient knee when compared to the intact knee prior to surgery ($12.2^\circ \pm 3.7^\circ$ and $10.7^\circ \pm 2.6^\circ$ respectively, $P=0.014$). Postoperatively, the ACLR knee showed significantly lower TR as compared to the ACL-deficient knee ($9.6^\circ \pm 3.1^\circ$, $P=0.001$) but no difference as compared to the control knee (n.s.). All functional scores were significantly improved and ATT was restored within normal values ($P < 0.001$).

✉ Frantzeska Zampeli
fzampeli@gmail.com; frangeska_zam@yahoo.gr

Ioannis Terzidis
jonterz@otenet.gr

João Espregueira-Mendes
jem@espregueira.com

Jim-Dimitris Georgoulis
jim.georgoulis@gmail.com

Manfred Bernard
ManfredBernard@aol.com

Evangelos Pappas
evpappas1@gmail.com

Anastasios D. Georgoulis
georgoulis.anastasios@gmail.com

² Orthopaedic Sports Medicine Center, Department of Orthopaedic Surgery, University of Ioannina, Ioannina, Greece

³ The-MIS, Center of Orthopaedic Surgery, Sports Medicine and Rehabilitation, St Luke's Hospital, Thessaloniki, Greece

⁴ Orthopaedics Department of Minho University, Minho, Portugal

⁵ Clínica do Dragão, Espregueira-Mendes Sports Centre - FIFA Medical Centre of Excellence, Porto, Portugal

⁶ Departement of Orthopaedic Surgery, Klinik Sanssouci, Helene-Lange, Potsdam, Germany

⁷ Discipline of Physiotherapy-Faculty of Health Sciences, The University of Sydney, Sydney, Australia

¹ 1st Department of Orthopaedics, ATTIKON University General Hospital, Haidari, Greece

Conclusions Intraoperative correction of tibiofemoral subluxation that results after ACL injury is an important step during anatomic SB ACLR. The intraoperative correction of tibiofemoral subluxation along with the replication of native ACL anatomy results in restoration of rotational kinematics of ACLD patients to normal levels that are comparable to the control knee. These results indicate that the reestablishment of tibiofemoral alignment during ACLR may be an important step that facilitates normal knee kinematics postoperatively.

Level of evidence Level II, prospective cohort study.

Keywords Anterior cruciate ligament · ACL reconstruction · Single bundle · Anatomic ACL reconstruction · Biomechanics · Rotational kinematics · Tibiofemoral subluxation

Introduction

Anterior cruciate ligament (ACL) reconstruction (ACLR) aims to restore knee joint function, stability and biomechanics which are compromised after ACL injury [28, 31, 45] and in this way to prevent the onset of early posttraumatic articular cartilage degeneration and the progression to osteoarthritis in the long term [2, 39].

Abnormal rotational kinematics of the knee during high demanding tasks that are present in ACL-deficient (ACL-D) patients, remains a problem even after a clinically successful ACLR [9, 10, 36, 43, 44]. This issue has been investigated by several studies but it has not yet been clearly and thoroughly understood what surgical techniques can facilitate normal rotational kinematics. Increasing evidence suggests that replicating the native ACL anatomy by placing the ACL graft at the anatomic footprints and by reproducing the

obliquity and dimensions of the native ligament can improve biomechanical and clinical outcomes [6, 8, 14, 20, 21, 33, 41, 43, 45]. Even though this results in improved clinical outcomes, the rotational kinematics are not re-established to normal levels [10, 14, 19, 27, 33, 35].

An under-investigated surgical parameter is the restoration of tibiofemoral subluxation (TFS) during ACL reconstruction. It has been suggested that restoring tibiofemoral position intraoperatively correlates to superior outcomes and restores knee joint biomechanics after ACLR [44]. Therefore, it is important to test if the correction of TFS intraoperatively before the graft is fixed may result in the correction of kinematics to normal level.

The hypothesis was that this technique restores normal knee joint kinematics that are disrupted after an ACL tear.

Materials and methods

Between 2009 and 2010, 62 ACL-D patients underwent arthroscopically assisted ACLR at our institution by the senior author. The inclusion and exclusion criteria for participating in the study are listed in Table 1. Only male patients were included in the study to improve sample homogeneity as it has been found that outcomes after ACLR differ between men and women [1, 37].

Out of 62 patients who underwent ACLR during the study period, 13 met the criteria and were offered participation. All eligible patients provided institutional review board-approved informed consent. All patients were athletically active individuals prior to ACL injury and suffered from at least one giving away episode from the time of injury during activities of daily living. In all cases, the ACL rupture was diagnosed by MRI, clinical examination

Table 1 Inclusion and exclusion criteria for participating in the study

Inclusion criteria

- (1) Anatomic SB ACLR using BPTB autograft for a complete, unilateral, isolated ACL rupture
- (2) No previous ACL injury to either knee
- (3) Male gender
- (4) Pre-injury activity level ≥ 7 according to Tegner activity score and desire to return to previous sports activity level after the ACLR
- (5) Minimum of 1 year follow-up

Exclusion criteria

- (1) Multiligament injuries (PCL and/or collateral ligament injuries along with the ACL rupture), serious coexistent chondral lesions (Outerbridge III/IV), meniscal injuries > 25% of meniscus, that required meniscectomy/suture repair at the time of ACLR
- (2) Prior ligamentous injury to the reconstructed or the contralateral knee, prior surgery on either knee or revision ACLR
- (3) Symptomatic anterior knee pain
- (4) Objective instability at the latest follow-up examination after ACLR (positive pivot-shift test, positive Lachman test and arthrometer KT-1000 SSD > 3 mm)

SB Single bundle, ACL anterior cruciate ligament, ACLR ACL reconstruction, BPTB bone-patellar tendon-bone, PCL posterior cruciate ligament, SSD side-to-side differences

Table 2 Patients' characteristics

Number	13
Gender	Male
Injured side (right/left)	10/3
Meniscal injury (medial/lateral)	7 (6/1)
Mean age (years)	26.4 (8, 17–43)
Mean height (m)	1.78 (0.06, 1.7–1.9)
Mean body mass (kg)	80.5 (7, 71–95)
Mean time from injury to operation (mo)	11.8 (8.2, 2–24)
Mean time of data collection (mo post-ACLR) ^a	14.9 (1.8, 12–18)

Parentheses include Standard Deviation, Range

ACLR Anterior cruciate ligament reconstruction

^aClinical examination, motion analysis

and confirmed arthroscopically during the ACLR procedure. Demographic data of the participants are presented in Table 2.

All clinical examination, functional and motion analysis tests were performed at two time points: before the surgery while the patients were ACL-D and more than 12 months after ACLR.

Clinical examination

A clinical examination was performed for all subjects by the same clinician who was not involved in the operation. Knee joint stability was tested via the Lachman-Noulis and pivot-shift tests. Anterior tibial translation (ATT) was measured using the KT-1000 knee arthrometer (MEDmetric Corp, San Diego, CA) for the ACL-D, ACL-R and contralateral intact knees. The measurements were performed using the 134N and maximum manual anterior force at the proximal tibia until heel clearance was achieved. Repeated anterior translations were performed until a constant reading on the dial was registered and the side-to-side difference (SSD) of ATT in mm was recorded for each participant.

Functional scores

Tegner activity level, Lysholm score [40], International Knee Documentation Committee (IKDC) subjective score, and IKDC grade [18] were obtained at both ACL-D and ACL-R state.

Motion analysis

An 8-camera optoelectronic three-dimensional (3D) motion analysis system (Vicon, Oxford, UK) sampling at 100 Hz was used to capture the trajectories of 16 reflective markers placed on selected bony landmarks of the lower extremities and pelvis using the model of Davis et al. [7]. Two force

platforms (type 4060-10; Bertec, Worthington, OH) that were flush mounted in the center of the calibrated volume were used to detect the touchdown of each leg of each participant during the task. Ground reaction force (GRF) data were collected at a sampling frequency of 1000 Hz and were synchronized with the Vicon system. Kinetic data were used to identify the beginning of pivoting (touchdown of the supporting leg).

All participants performed a dynamic pivoting activity consisting of descending from a stair and subsequent pivoting. The stairway was constructed according to Andriacchi et al. [4]. All subjects were given enough time (10 min) to warm up and familiarize themselves with the examined task. The experimental protocol was the same for every participant and was carried out by the same examiner. During the examined activity, the subjects descended the stairway at their own pace. After foot contact, the subject was instructed to perform a 90° pivoting maneuver on the supporting leg. While pivoting, the contralateral leg swung around the body (as it was coming down from the stairway) and at the end of pivoting, the trunk and foot were oriented perpendicular to the stairway. During the task, the points of touchdown for both legs (the supporting and the swinging leg) were indicated by floor marks to ensure the same 90° pivoting activity for all subjects. After pivoting, the subjects were instructed to walk away from the stairway for at least one stride. Each subject performed the activity on both legs (ACLR/ACLD) and contralateral intact leg which were tested in a randomized order. To achieve maximum knee rotational loading during the pivoting period, the subjects were instructed to keep the supporting foot in the same position until the contralateral foot contacted the ground (end of pivoting). A careful inspection of foot and trunk kinematics during real-time analysis allowed identifying the trials that fulfilled these requirements and a minimum of six successful trials were recorded for each side. In an effort to standardize the procedure as best as possible, the subjects were monitored in real time both visually and with software calculations to ensure that the trunk and pelvis were facing forward at the initiation of the pivoting task and at 90° at the end of the pivoting task. When deviations from these instructions were observed, the trial was repeated.

The evaluation period (pivoting phase) was identified from initial foot contact of the supporting (standing) leg with the ground and ended with touchdown of the contralateral leg [44]. To validate our procedures and minimize marker placement errors [23] regarding video capture of skin markers, an additional trial was recorded for each subject in anatomic position (with their feet parallel and 15 cm apart). This calibration allowed correction of subtle misalignment of the markers that define the local coordinate system and provided a definition of zero degrees for all segmental movements in all planes [44].

Data analysis

Anthropometric measurements were combined with 3D marker data from the anatomic position trial to provide positions of the joint centers and to define anatomic axis of joint rotations. The position of the markers provided the 3D segmental angles. The convention used for calculating knee rotations was based on Grood et al. [12]. The maximum and minimum TR values of the supporting leg during pivoting phase were identified. These two points were subtracted to acquire the range of motion (ROM) for TR during the pivoting phase. The selection of ROM instead of absolute values of tibial rotation eliminated errors reported in the literature [38, 42] when absolute measures (i.e., maximum or minimum) were used. The difference of TR ROM between the two knees was calculated by subtracting the TR ROM of the intact knee from the TR ROM of the ACL-reconstructed knee. This measure was named the side-to-side difference (SSD) TR ROM. This measure can quantify for each patient the “divergence” of the rotational motion that the ACL-reconstructed knee exhibits from the normal rotational motion of the contralateral healthy knee [43, 44].

Surgical technique

All surgeries were performed by the same orthopaedic surgeon (senior author). The bone-patellar tendon-bone (BPTB) graft was taken from the medial third of the patellar tendon with care to harvest no more than one-third of the total tendon width [11, 26]. The surgical technique has been described in detail elsewhere [44]. Briefly, the key points are that (a) the existing ACL footprint remnants were preserved when possible and used to place the graft as close to the anatomic position as possible. At the tibial footprint of the native ACL, the remnants were debrided and only the remnants up to 5 mm from the tibial attachment were preserved. This is the place where the native ACL widens and by doing this we can mimic the native ACL [17, 41]. The center of the femoral tunnel was drilled approximately at the center of the anatomic insertion of the ACL more towards the anteromedial bundle attachment [11, 15] with the knee joint in 120° of flexion [34]. The center of the tunnel position at the tibial plateau was placed approximately 5 mm anterior and medial to the anatomic center of the natural ACL attachment, so that the posterolateral part of the tunnel circumference was located on the anatomical center of the ACL attachment (Fig. 1). This was done to achieve placing the graft in the center of the anatomical tibial footprint of the native ACL by creating the tibial tunnel more anteriorly and medially [43]. (b) After the fixation to the femur, the graft was externally rotated 90° around its long axis, to replicate

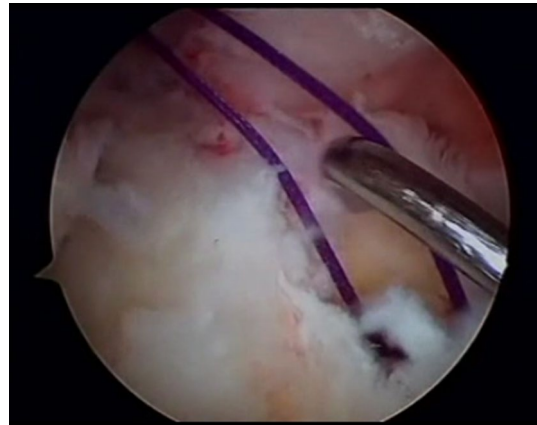


Fig. 1 This figure shows the tibial tunnel aperture that is created more anterior and medially. With the probe, we can facilitate the passing of the graft through the tibial tunnel and guide it to the correct position in the femoral tunnel

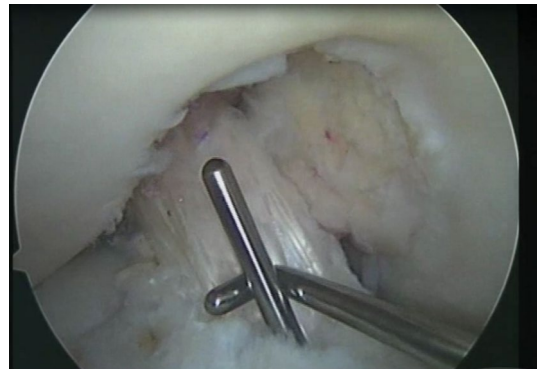

Fig. 2 The arthroscopic photo shows the final graft position during fixation at tibia. After the fixation to the femur, the graft was externally rotated 90° around its long axis, to replicate the natural rotation of the native ACL. At about 20–30° of flexion, maximal tension is applied manually, by pulling the graft from its patellar bone plug while centering the tibia by pushing it in posterior drawer position to correct the ATT and by rotating it externally to correct the internal rotation. To correct the tibiofemoral subluxation, the lower limb was retained at about the same position as the contralateral limb to adjust for the appropriate amount of external rotation. Holding the knee at this position and with the graft tensioned as described, we proceeded to the fixation on the tibia with the appropriately sized interference screw

the natural rotation of the native ACL. At about 20–30° of flexion maximal tension was applied manually, by pulling the graft from its patellar bone plug while centering the tibia by pushing it in posterior drawer position to correct the ATT and by rotating it externally to correct the internal rotation (Figs. 2, 3). To correct the tibiofemoral subluxation, the lower limb was retained at about the same position as the contralateral limb to adjust for the appropriate

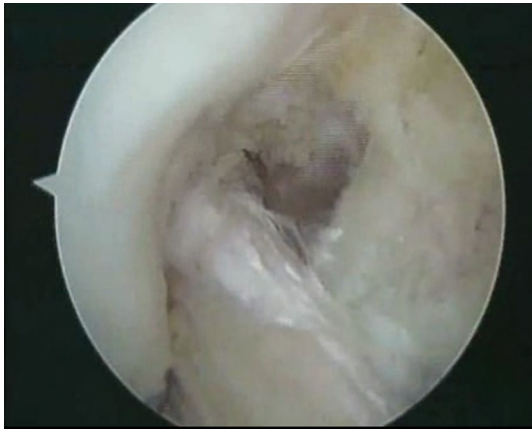

Fig. 3 Checking for impingement. The graft is placed anatomically at femur without impingement to the intercondylar roof or PCL in full extension or flexion. In addition, the graft is positioned more medially at the tibia avoiding impingement to the lateral femoral condyle and the PCL in full extension or flexion. One can see the triangular window between the femoral insertion of the graft and the femoral insertion of the PCL and also the appropriate distance between the distal part of the graft and the femoral condyle

amount of external rotation. The same rehabilitation protocol was used postoperatively for all patients.

Institutional review board (IRB) approval was given by the Medical School, University of Ioannina with decision number 1020, 27/01/2010.

Statistical analysis

Considering the small number of participants, it was necessary to test for data normality. Histograms and the Shapiro–Wilk test were used. As the tests were non-significant ($p \geq 0.257$), the data was deemed to be normally distributed and, thus, a repeated measures ANOVA was used with time (pre- and post-ACLR) and lower extremity (injured and intact) as the independent variables. Pairwise post-hoc tests were performed when interaction effects were significant. Paired t tests were performed to compare the ACL-D and ACL-R state regarding functional scores and ATT. To

examine the reliability, intraclass correlation coefficient (ICC) was calculated for the measurements of tibial rotation for the patients. An a priori power analysis was not performed for this project, however, the findings demonstrate that there was enough statistical power to detect differences in knee rotation of 2° or larger. Smaller differences would not be clinically relevant and would fall within the measurement error of the motion analysis systems [30]. A post-hoc power analysis revealed that we achieved 89% power for the main comparison for tibial rotation before and after the ACLR.

Results

All participants had completed at least 12 months from the operation date at the time of data collection. Patients' characteristics are shown in Table 2.

Clinical examination and functional scores

After ACLR, all patients regained objective stability as indicated by negative Lachman–Noulis and pivot-shift test postoperatively. The results for the ATT, the Lysholm, Tegner and IKDC scores as well as IKDC grade before and after ACLR are shown in Table 3.

Motion analysis: TR measurement

The repeated measures ANOVA revealed that there was a significant interaction for time \times leg ($p = 0.003$) as well as a main effect for time ($p = 0.003$) but no main effect for leg (n.s.). The interaction effect was further investigated with pairwise post-hoc tests that showed significantly higher TR of the ACL-D knee when compared to the control knee prior to surgery ($p = 0.014$) and to the ACL-R knee ($p = 0.001$). However, there was no difference in rotation of the control knee between the two measurements (n.s.) or between the two knees after surgery (n.s.) (Table 4). The results

Table 3 Clinical examination and functional score results

	ACL deficient	ACL reconstructed	<i>P</i> values
ATT SSD 134N (mm)	6 ± 2.4 , (3–10)	0.6 ± 0.8 , (–1–2)	<0.001
ATT SSD max man (mm)	6.3 ± 2 , (3–11)	1.1 ± 0.9 , (0–2)	<0.001
Lysholm score	67.3 ± 13.4 , (49–91)	93.3 ± 4.2 , (85–100)	<0.001
Tegner score	3 ± 1.2 , (1–5)	7.9 ± 1 , (7–9)	<0.001
IKDC subjective score	57.2 ± 13.4 , (37.93–78.16)	86.6 ± 9.7 , (68.96–98.85)	<0.001
IKDC grade (A/B/C/D)	0/3/7/3	11/2/0/0	

The results are expressed in mean \pm SD (range)

ATT Anterior tibial translation, SSD side-to-side differences, ACL anterior cruciate ligament, SD standard deviation, IKDC international knee documentation committee

Table 4 Tibial rotation ROM group mean values during the pivoting phase of the descending and pivoting task

ACL deficient		ACL reconstructed	
ACL-def knee	Contralateral intact knee	ACL-rec knee	Contralateral intact knee
12.25 (3.68) ^{a, b}	10.74 (2.58)	9.6 (3.16) ^c	10.43 (2.4)

Means and standard deviation (SD) values for range of motion (ROM) of the tibial rotation (degrees) for both knees for the ACL-deficient and -reconstructed state of the participants

ACL-def Anterior cruciate ligament deficient, *ACL-rec* anterior cruciate ligament-reconstructed, *ROM* range of motion

^aStatistical significant as compared to the contralateral intact knee, $p=0.014$

^bStatistical significant as compared to the ACL-rec knee, $p=0.001$

^cNo statistical significant as compared to the contralateral intact knee, n.s.

demonstrate high ICC 0.9 (95% CI 0.71–0.97) which shows acceptable repeatability for our measurement method.

Discussion

The most important finding of the present study was that the intraoperative correction of the TFS that is present in the ACLD knee offers excellent restoration of knee rotational kinematics and clinical outcomes, thus confirming the study hypothesis. This highlights the importance of TFS correction and demonstrates the need for not only replicating the anatomy of the native ACL but also carefully correcting tibiofemoral position during graft fixation. Thus, it appears that the anatomic approach of the ACLR presented in this study with restoration of pathologic TFS of ACLD knees can achieve optimal restoration of knee joint biomechanics.

When compared to previous studies, the results of the present study demonstrate for the first time that the restoration of rotational kinematics to normal values of control knee can be achieved. Prior studies have suggested that ACLR should replicate ACL anatomy by recreating as closely as possible the native ACL footprint with appropriate tunnel placement [25, 32, 35, 43], ligament obliquity [25, 33, 44], and morphology [41]. In the current study, all these factors were considered during the SBa-ACLR and besides, TFS was corrected intraoperatively. This comprehensive surgical approach may have contributed to the optimal restoration of knee joint kinematics that the previous studies with similar testing protocol did not achieve [43, 44]. The importance of the reduction of TFS can be easily recognized once we consider the role of ACL on knee joint biomechanics. After ACL rupture, both internal rotation and ATT increase, resulting in excessive movement of the lateral tibial plateau [28, 31, 45]. In the ACLD knee, the axis of rotation shifts more medially and the excessive TR coupled with ATT magnifies the movements of the tibial plateau and results in subluxation [3, 28, 31]. The need for restoration of the TFP

has been previously suggested in a study that investigated TFP and its correlation to the PCL index [44].

The correction of TFS is effective when performed with other necessary steps of anatomic ACLR. In this study, anatomic tunnel placement was individualized for each knee and was guided by the footprint of ACL remnants [22]. This results in graft obliquity comparable to that of the native ACL and correlates to improved tibiofemoral joint kinematics [25, 32, 43]. The center of the tibial socket was created about 5 mm anteriorly and medially to the center of the native footprint. This tibial tunnel position combined with anatomic femoral socket did not lead to impingement or loss of knee extension. Relevant literature has suggested the passage from the posterior tibial tunnel placement and notchplasty, which have both been recommended to avoid roof impingement, to the progressive tibial tunnel anteriorization [13, 25, 32, 43]. Previous studies showed that tibial tunnel placement in the anterior aspect of the native footprint confers increased sagittal graft obliquity and improved control of ATT after ACLR [25, 32, 43] but this may lead to notch impingement [25, 32]. Maak et al. showed that the AM tibial socket combined with the femoral socket into a more central position may reduce the risk of impingement [24].

Graft morphology is another key factor of the anatomic reconstruction concept [17, 24, 41]. It has been demonstrated that the ACL mid-substance and the femoral attachment have similar width resembling a band or “lasagna-like” shape, while about 5 to 6 mm before its tibial insertion, the ACL fans out like a trumpet, taking the form of its wide tibial attachment [17, 41]. In our study, we attempted to replicate the widened shape at the tibial footprint by preserving the remnants up to 5 mm from the tibial attachment. In contrast to a “fit and fill” technique where filling the footprint with a large graft will likely increase the risk for impingement, we suggest the use of a band-shaped graft along with remnant preservation as a way to imitate native ACL morphology and avoid impingement or loss of extension.

Regarding the study limitations, the use of skin markers in motion analysis has inherent error due to skin motion [23], however, we took precautions to minimize this error by having the same investigator place all markers and acquire all anthropometric measurements. In addition, the absolute 3D marker reconstruction error of the system was very low (maximum SD, 0.303 mm; calibration space, approximately 8 m³). A standing calibration procedure was used to correct for subtle misalignment of the markers that define the local coordinate system and for individual anatomic variations [5]. Finally, we chose to include a homogenous study group of male-only patients with BPTB graft which does not allow for generalization of our findings to female patients or patients who had hamstrings or allograft reconstructions. A study with a more heterogeneous sample would improve generalizability but that would be at the expense of internal validity. Other limitations are the small number of patients, the lack of quantitative means of proving that tibiofemoral subluxation is corrected at the time of surgery, and the relatively short follow-up period.

The results of the study indicate that the reestablishment of tibiofemoral alignment during anatomic ACLR before the final fixation of the graft at tibia may be an important step to achieve normal knee rotational kinematics postoperatively.

Conclusions

Intraoperative correction of tibiofemoral subluxation that results after ACL injury is a very important step during SBa-ACLR. In addition to replicating the native ACL anatomy, we should also correct the abnormal tibiofemoral subluxation during graft fixation. These steps result in absolute restoration of rotational kinematics of ACL-D patients in normal levels comparable to that of control knee.

Acknowledgements The authors gratefully acknowledge the funding support from the Hellenic Association of Orthopaedic Surgery and Traumatology (HAOST-EEXOT).

Compliance with ethical standards

Conflict of interest The authors declare that they have no conflict of interest.

Funding The authors received no financial support for the research, authorship, and/or publication for this article.

Ethical approval The study was approved by the Ethical committee of the institution that the study was conducted.

Informed consent Patients were informed, and they consented to conduct the study.

References

1. Ageberg E, Forssblad M, Herbertsson P, Roos EM (2010) Sex differences in patient-reported outcomes after anterior cruciate ligament reconstruction: data from the Swedish knee ligament register. *Am J Sports Med* 38:1334–1342
2. Ajuied A, Wong F, Smith C, Norris M, Earnshaw P, Back D, Davies A (2014) Anterior cruciate ligament injury and radiologic progression of knee osteoarthritis: a systematic review and meta-analysis. *Am J Sports Med* 42(9):2242–2252
3. Amis AA, Jakob RP (1998) Anterior cruciate ligament graft positioning, tensioning and twisting. *Knee Surg Sports Traumatol Arthrosc Suppl* 1:S2-12
4. Andriacchi TP, Andersson GBJ, Fermier RW, Stern D, Galante JO (1980) A study of lower-limb mechanics during stair-climbing. *J Bone Joint Surg Am* 62:749–757
5. Chambers H, Sutherland D (2002) A practical guide to gait analysis. *J Am Acad Orthop Surg* 10:221–231
6. Clancy WG (2015) Anatomic ACL reconstruction: the final answer? *Knee Surg Sports Traumatol Arthrosc* 23(3):636–639
7. Davis RB, Ounpuu S, Tyburski D, Gage JR (1991) A gait analysis data collection and reduction technique. *Hum Mov Sci* 10:575–587
8. Desai N, Alentorn-Geli E, van Eck CF, Musahl V, Fu FH, Karlsson J, Samuelsson K (2016) A systematic review of single- versus double-bundle ACL reconstruction using the anatomic anterior cruciate ligament reconstruction scoring checklist. *Knee Surg Sports Traumatol Arthrosc* 24(3):862–872
9. Geeslin AG, Civitarese D, Turnbull TL, Dornan GJ, Fuso FA, LaPrade RF (2016) Influence of lateral meniscal posterior root avulsions and the meniscofemoral ligaments on tibiofemoral contact mechanics. *Knee Surg Sports Traumatol Arthrosc* 24(5):1469–1477
10. Georgoulis AD, Papadonikolakis A, Papageorgiou CD et al (2003) Three-dimensional tibiofemoral kinematics of the anterior cruciate ligament-deficient and reconstructed knee during walking. *Am J Sports Med* 31(1):75–79
11. Georgoulis AD, Papageorgiou CD, Makris CA, Moebius UG, Soucacos PN (1997) Anterior cruciate ligament reconstruction with the press-fit technique. 2–5 years followed-up of 42 patients. *Acta Orthop Scand Suppl* 275:42–45
12. Grood ES, Suntay WJ (1983) A joint coordinate system for the clinical description of three-dimensional motions: application to the knee. *J Biomech Eng* 105:136–144
13. Hantes ME, Zachos VC, Liantsis A, Venouziou A, Karantanis AH, Malizos KN (2009) Differences in graft orientation using the transtibial and anteromedial portal technique in anterior cruciate ligament reconstruction: a magnetic resonance imaging study. *Knee Surg Sports Traumatol Arthrosc* 17:880–886
14. Herbolt M, Domnick C, Raschke MJ, Lenschow S, Förster T, Petersen W, Zantop T (2016) Comparison of knee kinematics after single-bundle anterior cruciate ligament reconstruction via the medial portal technique with a central femoral tunnel and an eccentric femoral tunnel and after anatomic double-bundle reconstruction: a human cadaveric study. *Am J Sports Med* 44(1):126–132
15. Hertel P, Behrend H, Cierpinski T, Musahl V, Widjaja G (2005) ACL reconstruction using bone-patellar tendon-bone press-fit fixation: 10-year clinical results. *Knee Surg Sports Traumatol Arthrosc* 13:248–255
16. Hoher J, Kanamori A, Zeminski J, Fu FH, Woo SL (2001) The position of the tibia during graft fixation affects knee kinematics and graft forces for anterior cruciate ligament reconstruction. *Am J Sports Med* 29:771–776

17. Irrarázaval S, Albers M, Chao T, Fu FH (2017) Gross, arthroscopic, and radiographic anatomies of the anterior cruciate ligament: foundations for anterior cruciate ligament surgery. *Clin Sports Med* 36(1):9–23
18. Irrgang JJ, Anderson AF, Boland AL, Harner CD, Kurosaka M, Neyret P, Rihmond JC, Shelbourne KD (2001) Development and validation of the International Knee Documentation Committee subjective knee form. *Am J Sports Med* 29:600–613
19. Kondo E, Yasuda K, Onodera J, Kawaguchi Y, Kitamura N (2015) Effects of remnant tissue preservation on clinical and arthroscopic results after anatomic double-bundle anterior cruciate ligament reconstruction. *Am J Sports Med* 43(8):1882–1892
20. Kopf S, Musahl V, Bignozzi S, Irrgang JJ, Zaffagnini S, Fu FH (2014) In vivo kinematic evaluation of anatomic double bundle anterior cruciate ligament reconstruction. *Am J Sports Med* 42:2172–2177
21. LaPrade RF, Moulton SG, Nitri M, Mueller W, Engebretsen L (2015) Clinically relevant anatomy and what anatomic reconstruction means. *Knee Surg Sports Traumatol Arthrosc* 23(10):2950–2959
22. Lu W, Wang D, Zhu W, Li D, Ouyang K, Peng L, Feng W, Li H (2015) Placement of double tunnels in ACL reconstruction using bony landmarks versus existing footprint remnant: a prospective clinical study with 2-year follow-up. *Am J Sports Med* 43(5):1206–1214
23. Lucchetti L, Cappozzo A, Cappello A, Croce UD (1998) Skin movement artifact assessment and compensation in the estimation of knee-joint kinematics. *J Biomech* 31:977–984
24. Maak TG, Bedi A, Raphael BS et al (2011) Effect of femoral socket position on graft impingement after anterior cruciate ligament reconstruction. *Am J Sports Med* 39(5):1018–1023
25. Malempati CS, Metzler AV, Johnson DL (2017) Single-bundle anatomic anterior cruciate ligament reconstruction: surgical technique pearls and pitfalls. *Clin Sports Med* 36(1):53–70
26. Moebius U, Georgoulis A, Papageorgiou C, Papadonikolakis A, Rossis J, Soucacos P (2001) Alterations of the extensor apparatus after anterior cruciate ligament reconstruction using the medial third of the patellar tendon. *Arthroscopy* 17:953–959
27. Mohtadi N, Chan D, Barber R, Oddone Paolucci E (2015) A randomized clinical trial comparing patellar tendon, hamstring tendon, and double-bundle ACL reconstructions: patient-reported and clinical outcomes at a minimal 2-year follow-up. *Clin J Sport Med* 25(4):321–331
28. Murawski CD, van Eck CF, Irrgang JJ, Tashman S, Fu FH (2014) Operative treatment of primary anterior cruciate ligament rupture in adults. *J Bone Joint Surg Am* 96(8):685–694
29. Nicholson JA, Sutherland AG, Smith FW (2011) Single bundle anterior cruciate reconstruction does not restore normal knee kinematics at six months: an upright MRI study. *J Bone Joint Surg Br* 93:1334–1340
30. Noehren B, Manal K, Davis I (2010) Improving between-day kinematic reliability using a marker placement device. *J Orthop Res* 28(11):1405–1410
31. Noyes FR, Jetter AW, Grood ES, Harms SP, Gardner EJ, Levy MS (2015) Anterior cruciate ligament function in providing rotational stability assessed by medial and lateral tibiofemoral compartment translations and subluxations. *Am J Sports Med* 43(3):683–692
32. Parkinson B, Robb C, Thomas M, Thompson P, Spalding T (2017) Factors that predict failure in anatomic single-bundle anterior cruciate ligament reconstruction. *Am J Sports Med*. doi:10.1177/0363546517691961
33. Porter MD, Schadbolt B (2014) “Anatomic” Single-bundle anterior cruciate ligament reconstruction reduces both anterior translation and internal rotation during pivot shift. *Am J Sports Med* 42(12):2948–2954
34. Prodromos CM, Brown C, Fu FH, Georgoulis AD, Gobbi A, Howell SM, Johnson D, Paulos LE, Shelbourne KD (2008) The anterior cruciate ligament: reconstruction and basic science. In: Bernard M, Ristanis S, Chouliaras V, Paessler H, Georgoulis A, The Anteromedial Portal for ACL Reconstruction, Chapter 19. Elsevier, Saunders, pp 129–133
35. Ristanis S, Stergiou N, Siarava E, Ntoulia A, Mitsionis G, Georgoulis A (2009) Effect of femoral tunnel placement for reconstruction of the anterior cruciate ligament on tibial rotation. *J Bone Joint Surg Am* 91(9):2151–2158
36. Saiegh YA, Suero EM, Guenther D, Hawi N, Decker S, Krettek C, Citak M, Omar M (2017) Sectioning the anterolateral ligament did not increase tibiofemoral translation or rotation in an ACL-deficient cadaveric model. *Knee Surg Sports Traumatol Arthrosc* 25(4):1086–1092
37. Shultz SJ, Beynnon BD, Schmitz RJ (2009) Sex differences in coupled knee motions during the transition from non-weight bearing to weight bearing. *J Orthop Res* 27(6):717–723
38. Stergiou N, Bates BT, James SL (1999) Asynchrony between subtalar and knee joint function during running. *Med Sci Sports Exerc* 31:1645–1655
39. Stergiou N, Ristanis S, Moraiti C, Georgoulis A (2007) Tibial rotation in anterior cruciate ligament (ACL)-deficient and ACL-reconstructed knees: a theoretical proposition for the development of osteoarthritis. *Sports Med* 37(7):601–613
40. Tegner Y, Lysholm J (1985) Rating systems in the evaluation of knee ligament injuries. *Clin Orthop Relat Res* 198:43–49
41. Triantafyllidi E, Paschos NK, Goussia A, Barkoula NM, Exarchos DA, Matikas TE, Malamou-Mitsi V, Georgoulis AD (2013) The shape and the thickness of the anterior cruciate ligament along its length in relation to the posterior cruciate ligament: a cadaveric study. *Arthroscopy* 29(12):1963–1973
42. Webster KE, McClelland JA, Wittwer JE, Tecklenburg K, Feller JA (2010) Three dimensional motion analysis of within and between day repeatability of tibial rotation during pivoting. *Knee* 17:329–333
43. Zampeli F, Ntoulia A, Giotis D et al (2012) Correlation between anterior cruciate ligament graft obliquity and tibial rotation during dynamic pivoting activities in patients with anatomic anterior cruciate ligament reconstruction: an in vivo examination. *Arthroscopy* 28:234–246
44. Zampeli F, Ntoulia A, Giotis D, Ristanis S, Mitsionis G, Pappas E, Georgoulis AD (2013) The PCL index correlates to the control of rotational kinematics that is achieved after anatomic ACL reconstruction. *Am J Sports Med* 42(3):665–674
45. Zantop T, Petersen W, Sekiya JK, Musahl V, Fu FH (2006) Anterior cruciate ligament anatomy and function relating to anatomic reconstruction. *Knee Surg Sports Traumatol Arthrosc* 14(10):982–992