

Mosaicplasty Using Grafts From the Upper Tibiofibular Joint



João Espregueira-Mendes, M.D., Ph.D., Renato Andrade, B.Sc., Alberto Monteiro, M.D., Hélder Pereira, M.D., Manuel Vieira da Silva, M.D., J. Miguel Oliveira, B.Sc., Ph.D., and Rui L. Reis, C.Eng., M.Sc., Ph.D., D.Sc., Doc.h.c.

Abstract: Autologous mosaicplasty has been widely used for the treatment of focal, full-thickness, articular cartilage lesions of the knee and ankle joints. Commonly, the autografts are harvested from non-weight-bearing areas of the knee joint, leading to associated donor-site morbidity and representing a considerable disadvantage. This Technical Note presents a mosaicplasty procedure for harvesting autologous osteochondral plugs from the upper tibiofibular joint to repair articular cartilage defects. With this technique, it is possible to achieve low or no risk of donor-site morbidity, being therefore a safe and favorable option to treat large cartilage defects. Because of its minimal size-related restrictions, it enables harvesting larger plugs (filling an area up to 5 cm²) without any additional iatrogenic complications. Hence, mosaicplasty using the upper tibiofibular joint autografts can overcome many of the reported complications associated with osteochondral autograft harvesting. Thus, the upper tibiofibular joint articular surface should be considered as a safe and reliable autograft source for harvesting osteochondral plugs.

Treating osteochondral cartilage defects still remains a challenge within the daily orthopaedic practice. Autologous osteochondral mosaicplasty is a one-step surgical technique that involves transplanting hyaline articular cartilage and subchondral bone from the

minimal weight-bearing areas of the knee. This technique aims to restore focal, full-thickness articular cartilage defects and thus achieve a congruous hyaline surface.¹ Scientific literature reports good long-term results in 72% of patients, with an overall failure rate of 28% and a reoperation rate of 19%.²

Mosaicplasty is known to yield several advantages. It is a one-step procedure, it can be applied to larger defects, providing both hyaline cartilage and subchondral bone, and has the capability to adapt according the defect geometry.^{1,3} Moreover, it provides a durable cartilage repair, it is less expensive than autologous chondrocyte

From the Orthopaedics Department of Minho University (J.E-M.), Minho; Clínica do Dragão, Espregueira-Mendes Sports Centre—FIFA Medical Centre of Excellence (J.E-M., R.A., A.M., J.M.O.); Dom Henrique Research Centre (J.E-M., R.A., A.M., H.P.), Porto; 3B's Research Group—Biomaterials, Biodegradables and Biomimetics, University of Minho, Headquarters of the European Institute of Excellence on Tissue Engineering and Regenerative Medicine, AvePark, Parque de Ciência e Tecnologia, Zona Industrial da Gandra, Barco (J.E-M., H.P., J.M.O., R.L.R.), Guimarães; ICVS/3B's—PT Government Associate Laboratory (J.E-M., H.P., J.M.O., R.L.R.), Braga/Guimarães; Faculty of Sports, University of Porto (R.A.), Porto; and Orthopaedic Department, Centro Hospitalar Póvoa de Varzim (H.P.), Vila do Conde, Portugal; Ripoll y De Prado Sports Clinic FIFA Medical Centre of Excellence (H.P.), Murcia-Madrid, Spain; and Orthopedic Surgery Department, Hospital de Braga (M.V.S.), Braga, Portugal.

The authors report that they have no conflicts of interest in the authorship and publication of this article. Full ICMJE author disclosure forms are available for this article online, as [supplementary material](#).

Received March 31, 2017; accepted July 14, 2017.

Address correspondence to João Espregueira-Mendes, M.D., Ph.D., Via Futebol Clube do Porto - F. C. Porto Stadium, Porto, Portugal. E-mail: espregueira@dlresearchcentre.com

© 2017 by the Arthroscopy Association of North America. Published by Elsevier. This is an open access article under the CC BY-NC-ND license (<http://creativecommons.org/licenses/by-nc-nd/4.0/>).

2212-6287/17466

<http://dx.doi.org/10.1016/j.eats.2017.07.022>

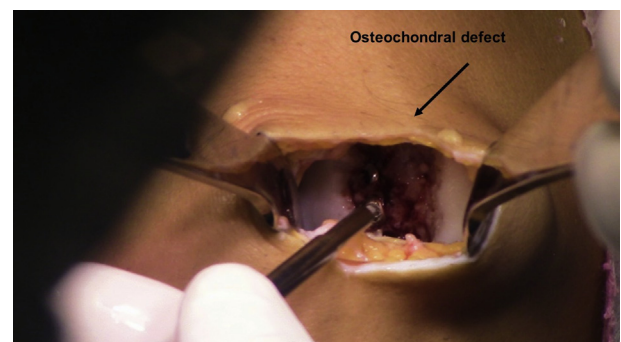


Fig 1. Dissection of the recipient site and examination of the articular cartilage defect. Osteochondral lesion is debrided and the borders of the defect are identified and regularized for graft preparation and measurement.

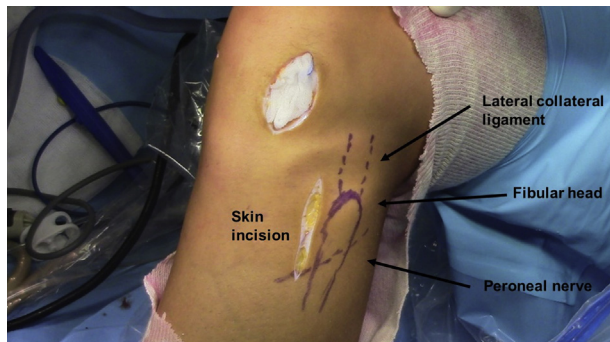


Fig 2. Drawing of the most relevant anatomic structures for surgical approach planning. Fibular head, lateral collateral ligament, and fibular nerve topography are identified by palpation, as the skin incision is delimited. The articular cartilage defect is covered with gauze pads.

implantation/matrix-induced autologous chondrocyte implantation, and provides immediate restoration of cartilage surface by treating the entire osteochondral unit.⁴ Nevertheless, osteochondral graft harvesting is usually associated with donor site morbidity.⁵ To overcome this concern, a limited number of studies used autologous osteochondral grafts from the upper tibiofibular joint for the treatment of knee articular cartilage lesions.^{3,6-8} Therefore, this technical report aims to comprehensively describe the mosaicplasty technique using autologous osteochondral grafts from the upper tibiofibular joint.

Patient Positioning and Osteochondral Defect Preparation

The patient is positioned in the standard supine position and the tourniquet is placed at the proximal thigh level. A dissection is made at the recipient site to explore the area of cartilage damage (Fig 1) and subsequently covered with gauze pads. The most relevant anatomic structures are drawn (Fig 2) and the peroneal nerve is identified through palpation and dissected if needed (Video 1).

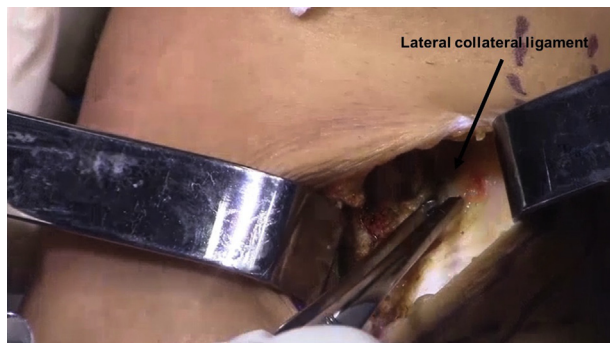

Fig 3. After superficial skin incision, the lateral collateral ligament is identified. This may be better accomplished with the knee in varus position for tensioning this structure.

Table 1. Surgical Pearls, Pitfalls, Advantages, and Limitations

Pearls	Pitfalls
Important to preserve the “safe zone,” avoiding damage to the common peroneal nerve, the anterior tibial artery, biceps tendon attachment and the lateral collateral ligament	When opening the joint capsule, if proper caution is not taken, the lateral collateral ligament and biceps tendon attachments could be damaged
After the medial aspect of the fibular head is dissected, moving the fibula head will allow visualization of the entire joint	Special attention should be taken when making the fibular head horizontal cut to avoid peroneal nerve damage
While making the vertical cut on the fibular head, angle the blade 45° out, parallel to the collateral ligament	While drilling the plug, if proper irrigation is not used, the cartilage may be damaged as a result of drill friction
When making the tibial vertical cut, be cautious to not pass the guide line to protect the tibial plateaus	
While drilling the osteochondral plugs, place the guide on the periphery of the articular surface to maximize the number of plugs	
While inserting the osteochondral plugs, rotate the plug to achieve the best fit	
Advantages	Limitations
Autografts from the upper tibiofibular joint lead to low or no risk for donor-site morbidity	Younger patients, until 45-50 years old
This technique has fewer size-related restrictions, enabling to harvest larger plugs (up to a total of 5 cm ²) without any additional iatrogenic complications	Restricted to the quality of the recipient’s site surrounding articular cartilage (e.g., progressive osteoarthritis)
It is possible to make up to 6 plugs of 6 mm each	

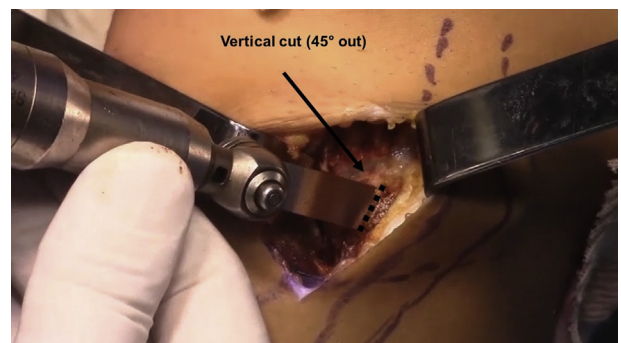


Fig 4. The medial aspect of the fibular head is vertically sawed with an oscillating saw at 45° out (parallel to the lateral collateral ligament), until the fibular neck is reached. Special attention is paid to the saw angle to preserve posterolateral structures. The lateral collateral ligament and biceps tendon attachment must also be preserved.

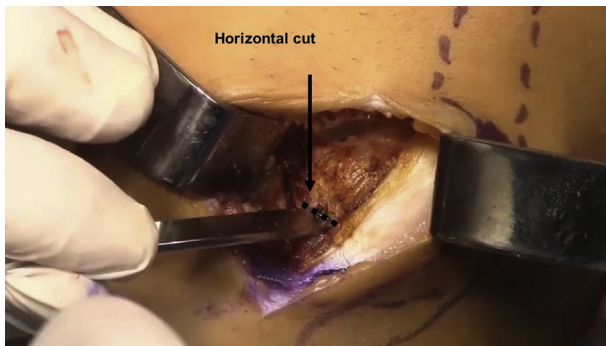


Fig 5. Second cut (horizontal cut) is performed transversely on the lower part of the fibular head, just above the peroneal nerve, perpendicular to the first cut. The length of the cut should be augmented by a 1-cm osteotome.

Osteochondral Harvesting

Surgical Approach

A vertical skin incision is made 1 cm anterior to the fibular head and 1 cm above the tip of fibula head, continuing 4 to 5 cm down. Through an anterior approach, a blunt dissection is made until the fibular neck and lateral collateral ligament can be felt to approach the upper tibiofibular joint capsule. As soon as the lateral collateral ligament is identified (Fig 3), the joint capsule is properly divided. Special caution should be taken or the common peroneal nerve, the anterior tibial artery, and the lateral collateral ligament could be damaged (Table 1). The common peroneal nerve was found to be approximately 19.5 mm below the inferior part of the knee joint.⁹ This distance can be considered as a “safe zone” to approach the upper tibiofibular joint, and therefore must be preserved along the lateral collateral ligament and biceps tendon insertion.

Fibular Head Partial Resection

The medial aspect of the fibular head is then vertically sawed (parallel to the collateral ligament) with an oscillating saw until the fibula neck is reached. Special

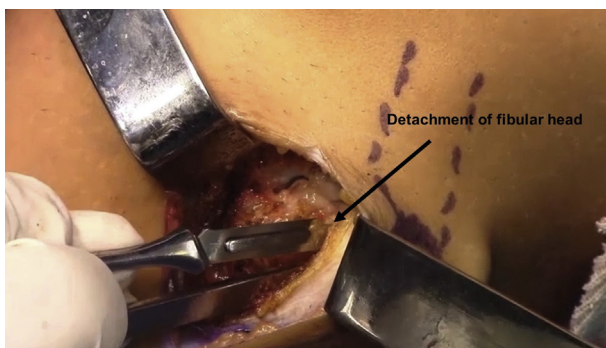


Fig 6. After the vertical and horizontal cuts, the fibular head is detached with a scalpel. The peripheral soft tissue should also be released.

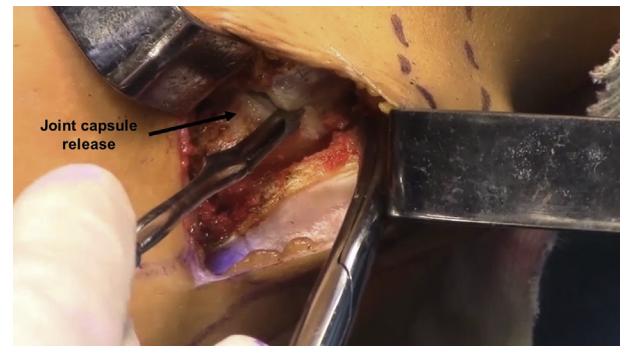


Fig 7. With a scalpel, the joint capsule must be released to allow removal of the fibular head.

attention should be paid to the blade angle, which should be guided 45° out to preserve the posterolateral structures (Fig 4). A second cut is performed transversely on the lower part of the fibular head, just above the peroneal nerve, perpendicular to the first one. The length of the cut is augmented by an osteotome and, with a 1-cm osteotome, the surgeon completes the fibular head osteotomy (Fig 5). With these 2 cuts, the fibular head should be detached with a scalpel (Fig 6). Additionally, the joint capsule is completely released with a scalpel (Fig 7), as well as the posterior ligament with a scissor (Fig 8). At this point, the osteochondral block with 12 to 15 mm in depth is removed from the joint, held at the cortical bone level (Fig 9).

Tibial Side Osteochondral Resection

Once the fibular osteochondral block is removed, a 1.5-cm guide line from the cartilage surface of the tibial side is drawn to harvest the tibial side (Fig 10). Just as the previous procedure, a vertical cut (up to 1.5 cm) is performed at the anterior limit of the cartilage surface (Fig 11). Caution should be taken while performing the vertical cut, to not cross the guide line or it might damage the tibial plateau. A horizontal cut on the guide line is made, from the anterior until the posterior limits of the joint, and then augmented with a 1-cm osteotome. The osteochondral block is held at the cortical

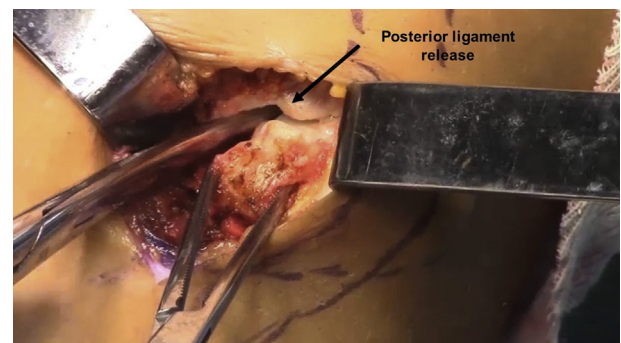


Fig 8. The posterior ligament must also be released using scissors to ease fibular head removal.

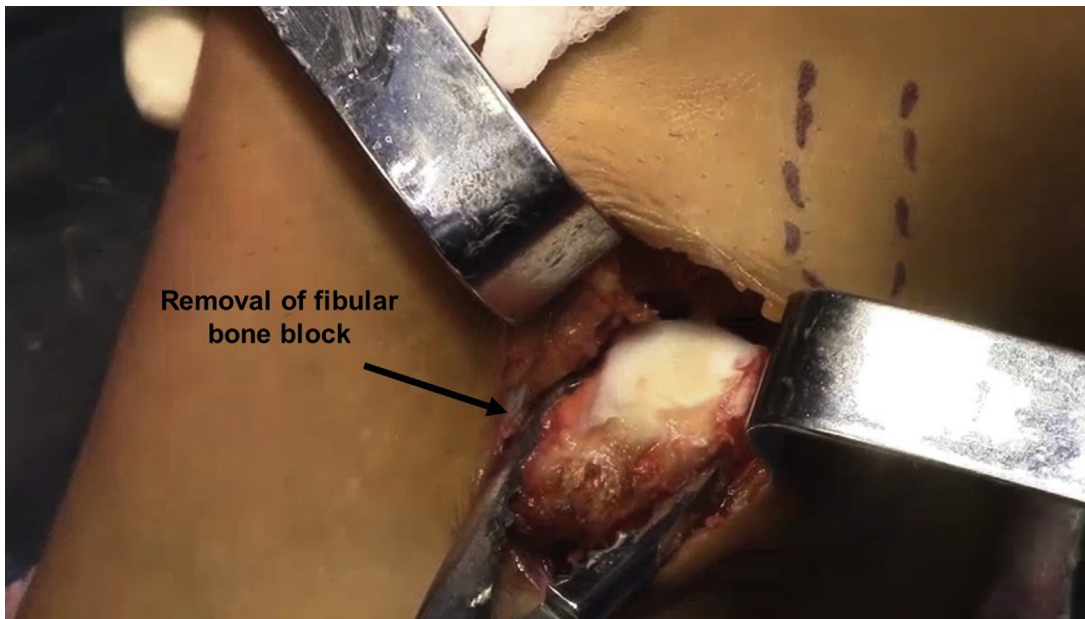


Fig 9. Remove the fibular head osteochondral block by holding at the cortical bone level. The osteochondral block is usually 12-15 mm in depth.

level, and the posterior part is released with scissors. In the same line, an osteochondral block is removed from the tibial side, creating a wider and thicker cartilage osteochondral block.

Closure

A subcutaneous fat pad should be added to avoid the joint fusion. At this point, the upper tibiofibular joint space should be properly closed ([Fig 12](#)).

Osteochondral Plug Preparation

The next step is to transform the cartilage autografts into osteochondral plug cylinders. The osteochondral block is held in a hard surface and the guide is placed on the cartilage periphery to maximize the number of plugs. The drill should be performed at slow speed, while it is simultaneously irrigated. The cylinder is then removed from the drill, and this procedure is repeated until the osteochondral blocks run out of available

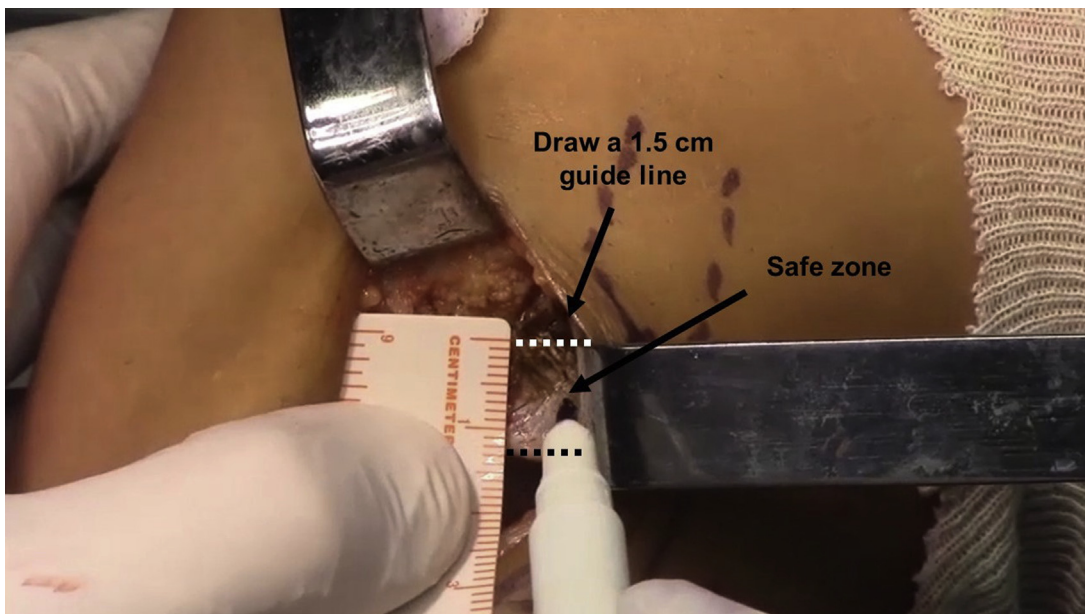


Fig 10. Once the fibular osteochondral block is removed, a 1.5-cm guide line from the lower cartilage end surface of the tibial side is drawn to harvest the tibial side. This guide line will aid the surgeon to limit the vertical cut to the safe zone.

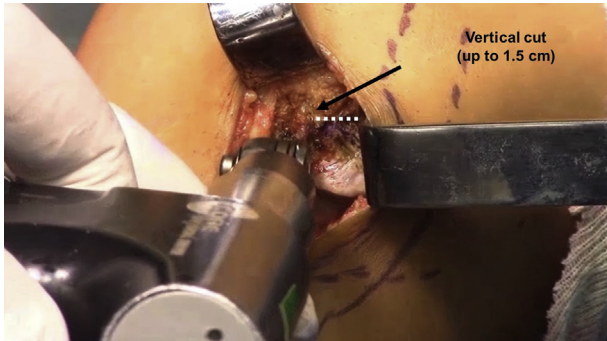


Fig 11. A vertical cut (up to 1.5 cm) is made in the tibial side at the anterior limit of the cartilage surface. It is crucial to apply caution and not surpass the guide line to protect the tibial plateau (i.e., to keep the vertical cut within the safe zone).

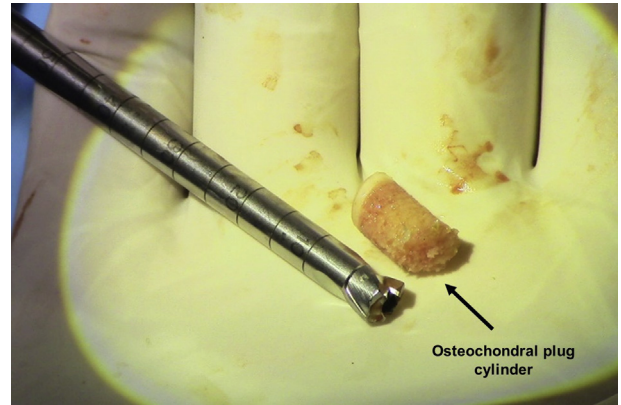


Fig 14. After graft drilling, several osteochondral plug cylinders should be created manually.

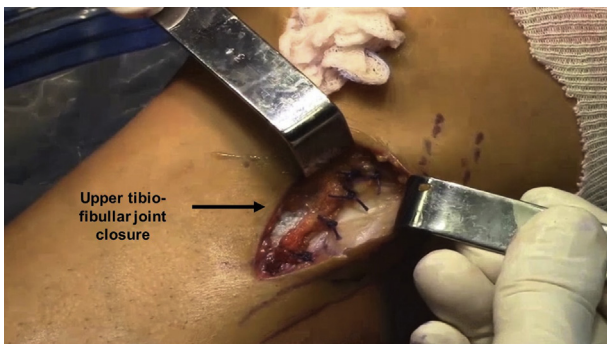


Fig 12. A subcutaneous fat pad is added to avoid joint fusion. At this point, the upper tibiofibular joint space should be properly closed.

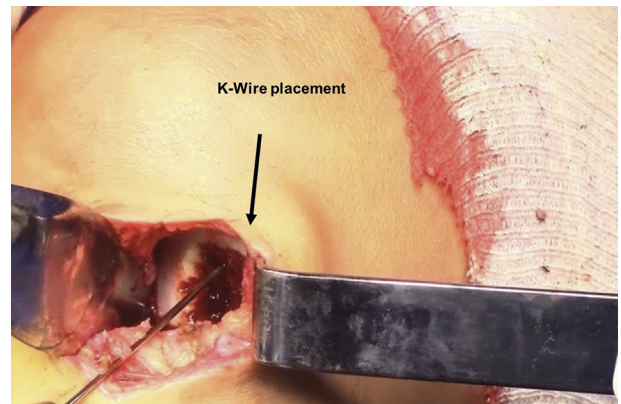


Fig 15. The K-wire is placed in the center of the first plug area for creating a hole with the same length as the osteochondral plug. This can be accomplished with a drill 0.5 mm larger than the graft plug.

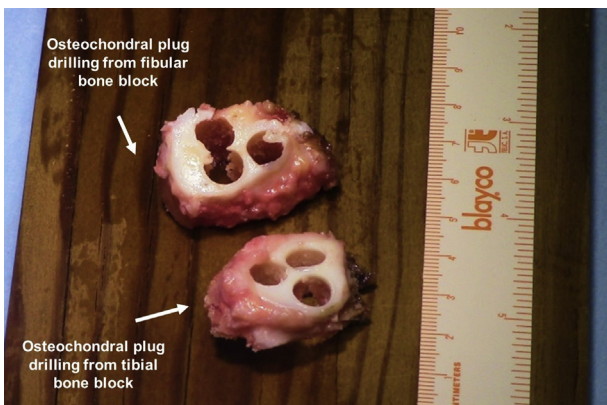


Fig 13. The autologous articular cartilage is drilled to create osteochondral plug cylinders. The osteochondral block is held in a hard surface and the guide is placed from the cartilage periphery to its center to maximize the number of osteochondral plugs.

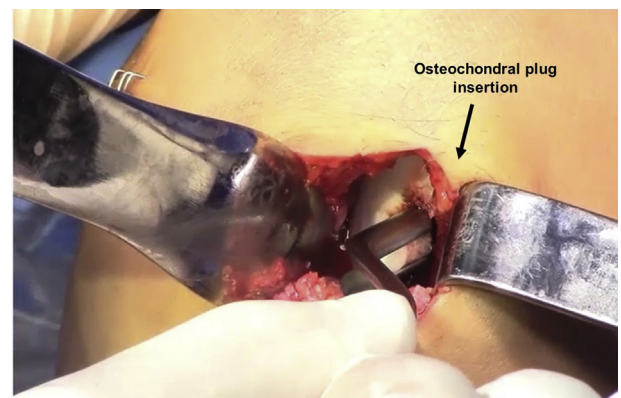

Fig 16. The osteochondral plug is inserted in the created hole and eased by rotation. The osteochondral plug must be stable, and the articular cartilage surface must be continuous and without any irregularities.

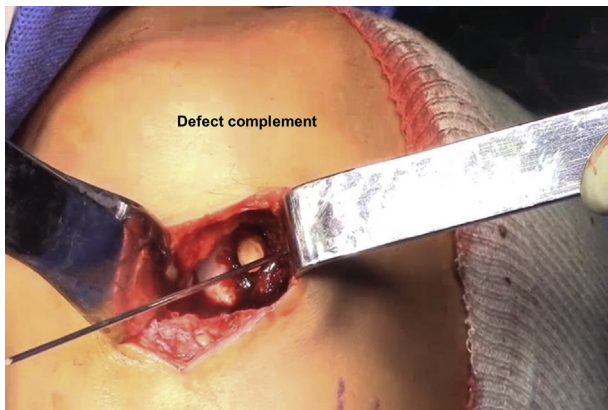


Fig 17. The last step is repeated until the articular cartilage defect is covered. The articular cartilage defect must be continuously covered and the final result must be stable enough to avoid future graft loosening and subsequent failure. Nevertheless, caution should be taken to perform independent holes, without any communication between them. Attention to this point is important to ensure better stabilization of the reconstructed osteochondral graft.

cartilage surface (Fig 13). From these autografts, it is possible to make several osteochondral hyaline cartilage cylinders, that is, the osteochondral plugs (6 mm and up to 10 mm), through a trephine (Smith & Nephew, Andover, MA; Fig 14). The osteochondral graft can also be customized to fill the defect.

Osteochondral Plug Grafting

After the creation of the osteochondral plugs, the surgeon prepares the recipient site for receiving the cylindrical osteochondral plugs. In this sense, the osteochondral defect is cleaned, the borders are stabilized, and subchondral bone is stimulated. Then, the plugs should be first placed at the periphery of the defect. Hence, a K-wire is placed at the center of the first plug area (Fig 15) and a hole is made of the same length as the plug, with a drill 0.5 mm larger than the graft plug. The plug is then gently inserted into the hole, which can be eased by rotating the plug until the best fit is obtained (Fig 16). The procedure is repeated for the other plugs until the defect area is covered (Fig 17).

A previous work described that with osteochondral autografts from the upper tibiofibular joint, it is possible to fill in defect areas up to 5 cm² (Fig 18).³ The key points of the surgical procedure are described in Table 2.

Rehabilitation and Follow-up Imaging

The patient is advised to ambulate non-weight-bearing with crutches for 4 to 6 postoperative weeks. Then, partial weight-bearing is allowed in the following 2 to 4 weeks, depending on the number of

osteochondral plugs used and on the stability of the graft. Passive mobilization of the knee is started as soon as the knee effusion decreases and is dependent on the tolerated pain. Continuous passive motion is also implemented at this stage. Active knee motion without weight-bearing is encouraged as tolerated. Knee range of motion is not restricted. Full weight bearing is achieved at 7 to 8 postoperative weeks. Then, the rehabilitation is focused in regaining symmetric lower limb strength and function, as well as restoring a normal gait pattern. The imaging follow-up procedures are performed to assess the graft's osteointegration. At 3 months postoperation, a computed tomography is performed. A magnetic resonance imaging scan is suggested at the 6-month follow-up.

Discussion

One keystone to succeed in cartilage repair is to achieve a new congruous hyaline or a hyaline-like gliding surface over the articular cartilage defect. Circumscribed chondral or osteochondral defects of the weight-bearing gliding surfaces of the knee may lead to an early onset of osteoarthritis.⁶ Mosaicplasty arises as a potential surgical technique for young patients with small cartilage defects of the joints, resulting in good long-term clinical outcomes.¹⁰ A systematic review included 9 prospective comparative studies, including a total of 607 patients with full-thickness articular cartilage injuries, with a minimum of 12-month follow-up, that compared the mosaicplasty procedure with other treatment modalities.¹¹ The authors could not establish any superiority of one surgical procedure over another because of several limitations. Nevertheless, after assessing the radiographs and magnetic resonance images at long-term follow-up, they reported incorporation of the osteochondral plugs with restoration of the

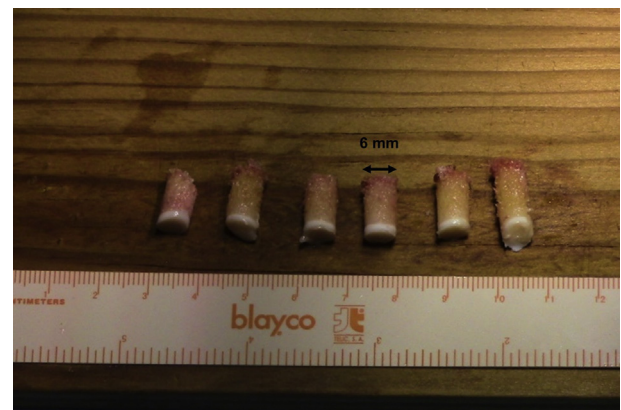


Fig 18. From the osteochondral block grafted from the upper tibiofibular joint, it is possible to create a total of 6 plugs of 6 mm diameter each (up to 10 mm). This allows to fill in defect areas up to 5 cm².

Table 2. Surgical Procedure Key Points**Surgical Approach**

- Dissect the recipient site to explore the cartilage damage area.
- Draw the anatomic structures and identify the peroneal nerve by touch

Fibular head osteotomy

- Make a 4-5-cm vertical incision, 1 cm anterior to the fibular head and 1 cm above the tip of the fibula head
- Identify the peroneal nerve and dissect it if needed
- Make a blunt dissection through an anterior approach until the fibular neck and lateral collateral ligament can be felt.
- Open the joint capsule and dissect the medial aspect of the fibular head
- Make a vertical cut parallel to the collateral ligament, with a 45° out angle
- Perform a horizontal cut in the lower part of the fibular head, just above the peroneal nerve
- Increase the length of the cut with an osteotome and complete the osteotomy with a thin osteotome (1 cm)
- Carefully detach the osteochondral block from the fibular head with a scalpel
- Release completely the joint capsule with scalpel and the posterior ligament with scissors
- Remove the fibular head by holding it at the cortical bone level

Tibial head osteotomy

- Mark a guide line 1.5 cm above the tibial joint surface
- Make a vertical cut on the anterior limit of the joint, up to 1.5 cm (guide line), and a horizontal cut on the guide line, from the anterior to the posterior limit of the joint
- Complete the cut with a thin osteotome (1 cm)
- Hold the osteochondral block by the cortical bone and release the posterior part with scissors
- Close the upper tibiofibular joint

Osteochondral plug preparation and grafting

- Stabilize the block in a hard surface and drill the plugs starting at low speed, and always use simultaneous irrigation
- Remove the plug from the drill and repeat the procedure until it runs out of cartilage surface
- Clean the defect, stabilize the borders, and stimulate the subchondral bone
- Verify the depth of the osteochondral plug and start placing them at the defect periphery
- Place the K-wire in the center of the first plug area and drill the length of the plug with a drill 0.5 mm larger than the plug autograft
- Gently insert the plug into the hole and repeat the procedure with the remaining plugs

articular surface and only a slight presence of osteoarthritis. Greater return-to-sport rates within the preinjury level were reported for mosaicplasty (93%) when compared with the microfracture procedure (52%), both with a mean time to return to competition at the preinjury level of 6.5 months.¹²

Despite the good results reported in the scientific literature, the mosaicplasty procedure is limited to young patients and restricted cartilage defect sizes. Moreover, concomitant surgical interventions and defects located in the medial femoral condyle can lead

to inferior results.¹³ Beyond that, harvesting grafts from non-weight-bearing areas of the knee joint may lead to donor-site morbidity.^{5,14} In this sense, this mosaicplasty modified technique avoids donor-site morbidity by obtaining the graft from the upper tibiofibular joint. No complications on the common peroneal nerve, the anterior tibial artery, and the lateral collateral ligament have been reported.³

Within the indications of the mosaicplasty, the upper tibiofibular joint has fewer size-related restrictions, once it enables to harvest larger plugs without any

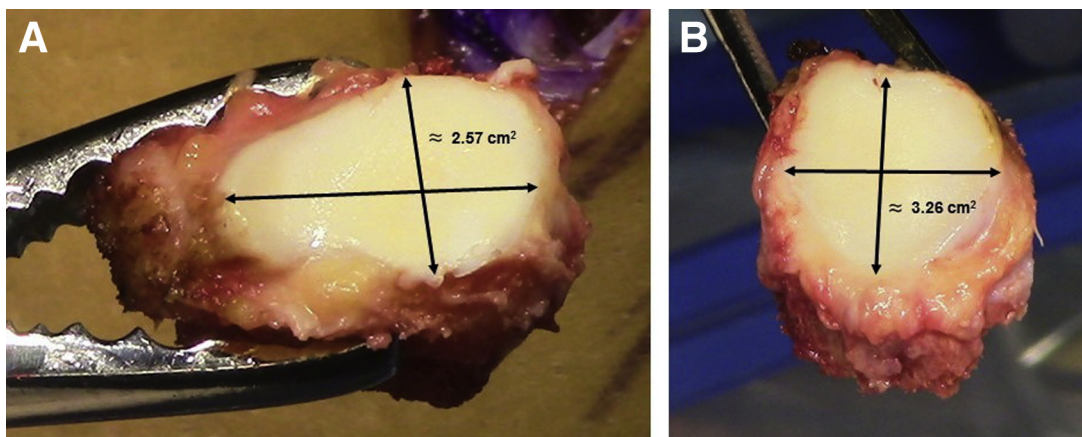


Fig 19. The fibular and tibial articular cartilage surface from the upper tibiofibular joint are available for autografting osteochondral plugs, filling up an area of approximately 5 cm². (A) Available fibular articular joint surface of the upper tibiofibular joint (± 2.57 cm²); (B) available tibial articular joint surface of the upper tibiofibular joint (± 3.26 cm²).

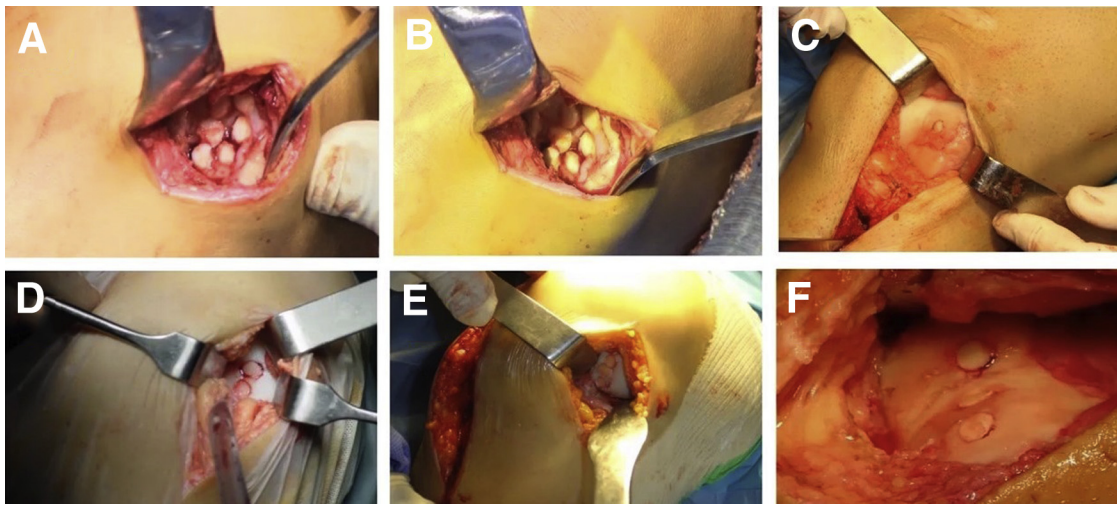


Fig 20. Intraoperative view of articular cartilage defects filled with implanted osteochondral plugs from the upper tibiofibular joint. Various numbers of osteochondral plugs may be used, depending on the size of the articular cartilage defect: (A, B) 6 osteochondral plugs implanted; (C, E, F) 3 osteochondral plugs inserted; and (D) 2 osteochondral plugs implanted. The articular cartilage reconstructed surface must be smooth and stable.

additional iatrogenic complications.^{3,6} In addition, Espregueira-Mendes and Vieira da Silva⁹ described the upper tibiofibular joint anatomy and histology of 20 fresh cadavers, reporting a mean tibial surface area of 3.26 cm² and a mean fibular surface area of 2.57 cm² (total area larger than 5 cm²), with 2 possible configurations of these joints: plane or L-shaped (either trochoid or double trochoid). These characteristics make the upper tibiofibular joint an available option for articular defects of the knee (Fig 19).

Notwithstanding, the mosaicplasty procedure has its limitations. In patients with inflammatory disease, collagen disease, or in patients older than 45 years who already have progressive osteoarthritis, additional care should be taken during incorporation of the grafts because the plugs need a healthy biochemical environment to support their nutrition¹⁵ (Table 1).

Using this approach, it is possible to avoid donor-site morbidity and consider performing this procedure in larger cartilage defects. Mosaicplasty using the upper tibiofibular joint autograft can overcome the many associated complications of this procedure and should be considered by the orthopaedic surgeon as a safe and reliable option for treating knee osteochondral defects (Fig 20).

Acknowledgment

The authors sincerely acknowledge André Silva, Ana Leal, and Prof. Ricardo Bastos for their valuable help regarding the construction and management of the video and figures.

References

1. Hangody L, Kish G, Karpati Z, Szerb I, Udvarhelyi I. Arthroscopic autogenous osteochondral mosaicplasty for the treatment of femoral condylar articular defects: A preliminary report. *Knee Surg Sports Traumatol Arthrosc* 1997;5:262-267.
2. Pareek A, Reardon PJ, Maak TG, Levy BA, Stuart MJ, Krych AJ. Long-term outcomes after osteochondral autograft transfer: A systematic review at mean follow-up of 10.2 years. *Arthroscopy* 2016;32:1174-1184.
3. Espregueira-Mendes J, Pereira H, Sevivas N, et al. Osteochondral transplantation using autografts from the upper tibio-fibular joint for the treatment of knee cartilage lesions. *Knee Surg Sports Traumatol Arthrosc* 2012;20:1136-1142.
4. Ollat D, Lebel B, Thaunat M, et al. Mosaic osteochondral transplantations in the knee joint, midterm results of the SFA multicenter study. *Orthop Traumatol Surg Res* 2011;97: S160-S166.
5. Andrade R, Vasta S, Pereira R, et al. Knee donor-site morbidity after mosaicplasty—A systematic review. *J Exp Orthop* 2016;3:31.
6. Jerosch J, Filler T, Peuker E. Is there an option for harvesting autologous osteochondral grafts without damaging weight-bearing areas in the knee joint? *Knee Surg Sports Traumatol Arthrosc* 2000;8:237-240.
7. Jerosch J, Filler TJ, Peuker ET. The cartilage of the tibio-fibular joint: A source for autologous osteochondral grafts without damaging weight-bearing joint surfaces. *Arch Orthop Trauma Surg* 2002;122:217-221.
8. Espregueira-Mendes J, Cabral T, Teles C, da Silva B, Lima P. Tratamento de Osteocondrite Dissecante do joelho com um novo enxerto osteocartilagíneo de peróneo—A propósito de um caso clínico. *Rev Port Ortop Traumatol* 1983;1:181-183.

9. Espregueira-Mendes J, Da Silva MV. Anatomy of the proximal tibiofibular joint. *Knee Surg Sports Traumatol Arthrosc* 2006;14:241-249.
10. Filardo G, Kon E, Perdisa F, Tetta C, Di Martino A, Marcacci M. Arthroscopic mosaicplasty: Long-term outcome and joint degeneration progression. *Knee* 2015;22:36-40.
11. Lynch TS, Patel RM, Benedick A, Amin NH, Jones MH, Miniaci A. Systematic review of autogenous osteochondral transplant outcomes. *Arthroscopy* 2015;31:746-754.
12. Gudas R, Stankevičius E, Monastyreckienė E, Pranys D, Kalesinskas RJ. Osteochondral autologous transplantation versus microfracture for the treatment of articular cartilage defects in the knee joint in athletes. *Knee Surg Sports Traumatol Arthrosc* 2006;14:834-842.
13. Emre TY, Ege T, Kose O, Demircioglu DT, Seyhan B, Uzun M. Factors affecting the outcome of osteochondral autografting (mosaicplasty) in articular cartilage defects of the knee joint: Retrospective analysis of 152 cases. *Arch Orthop Trauma Surg* 2013;133:531-536.
14. Valderrabano V, Leumann A, Rasch H, Egelhof T, Hintermann B, Pagenstert G. Knee-to-ankle mosaicplasty for the treatment of osteochondral lesions of the ankle joint. *Am J Sports Med* 2009;37:105S-111S.
15. Kish G, Modis L, Hangody L. Osteochondral mosaicplasty for the treatment of focal chondral and osteochondral lesions of the knee and talus in the athlete. Rationale, indications, techniques, and results. *Clin Sports Med* 1999;18:45-66, vi.