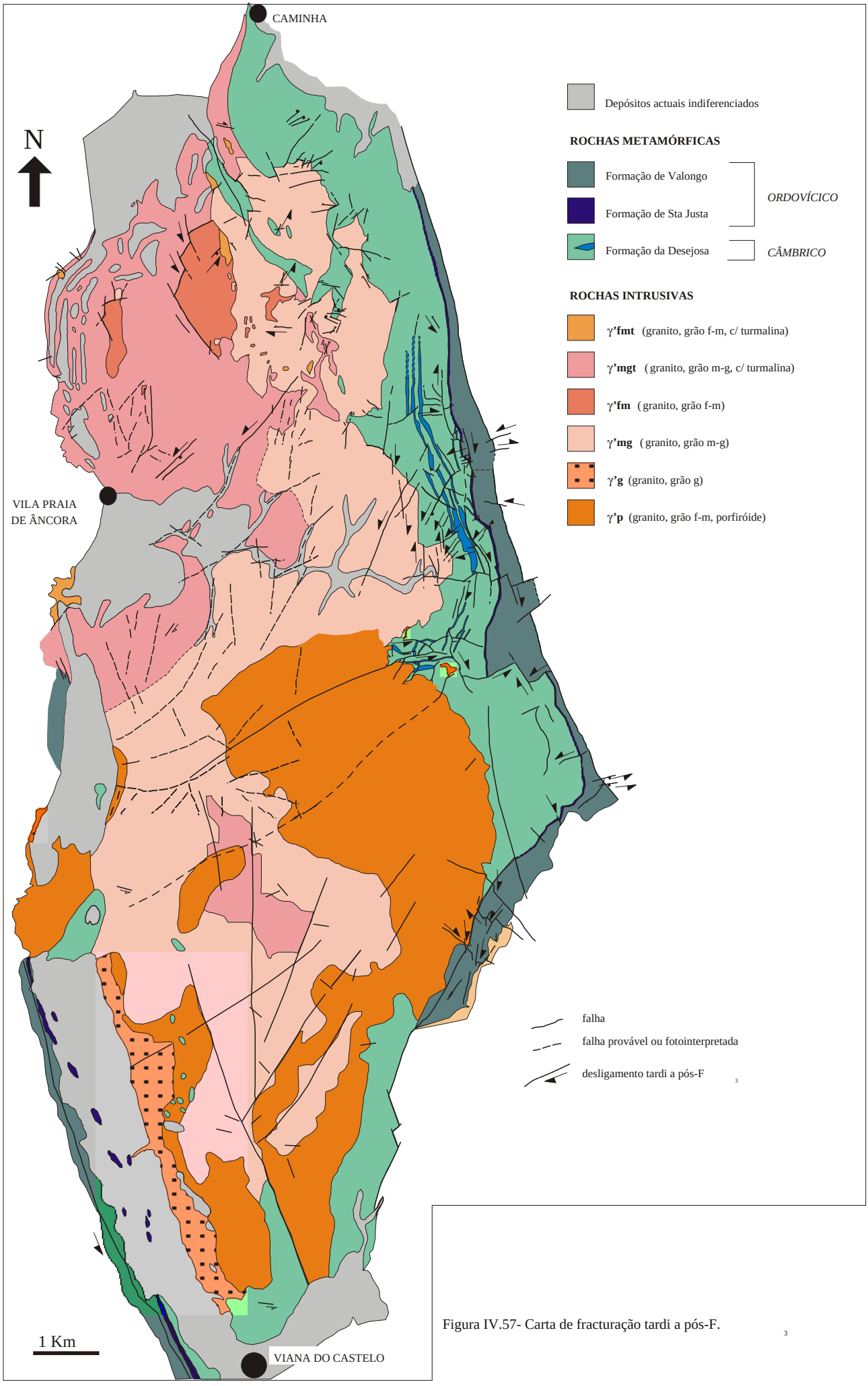

Figura IV.57- Carta de fracturação tardi a pós-F.